



सत्यमेव जयते  
Department of Science and Technology  
Government of India

Department of Science & Technology  
Ministry of Science & Technology

# An Efficient Automated Method for Exudates Segmentation using Image Normalization and Histogram Analysis

Ashmita Gupta, Ashish Issac, Namita Sengar, Malay Kishore Dutta  
Department of ECE, Amity School of Engineering & Technology,  
Amity University, Noida, India



## Abstract

Exudates are one of the abnormalities present on the retina which can be used in identification of diseases like Diabetic Retinopathy and Macular Edema. There arises a need for automated and correct segmentation of exudates from fundus images. This paper proposes an automated computer vision technique for efficient exudates segmentation from fundus images. The proposed method segments the exudates using an adaptive intensity based threshold which is selected by strategically combining first order statistical parameters and local thresholding method. The proposed technique correctly detects exudates from the fundus images with an average computation time of 9 seconds. The proposed method is computationally strong and can be used in image processing based applications for diagnosis of ocular diseases.

## Proposed Algorithm

Retinal exudates are lipid residues that leak from damaged capillaries and commonly seen in diabetic retinopathy, retinal vein occlusions and choroid neo-vascular membranes. Exudates may be considered small regions of bright yellow color in the eye which can be rich in protein and fat.

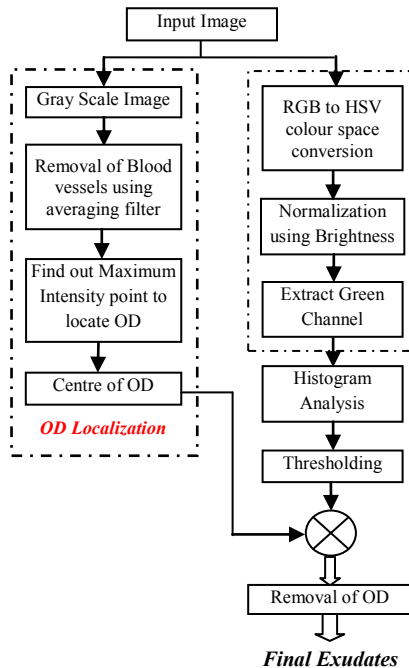


Fig.1. Flow Diagram of Proposed Algorithm

The method for automatic exudates segmentation from fundus image proposed in the paper can be categorized into three main subsections which are image normalization, removal of false positives and final detection and segmentation of exudates using histogram analysis of fundus images as shown in fig.1.

### A. Preprocessing:

A color fundus image consists of 3 channels, blue, green and red. The green channel has been used in proposed work. A need to normalize the images arises to bring uniformity in the color of the images, the v-channel of the HSV color space is smoothed using a median filter. The smoothed v-channel  $V(i,j)$  is used to update all the 3 channels in the RGB color space using  $Bc(i,j)$  values which is calculated as follows:

$$Bc(i,j) = \sqrt{1 - \{V(i,j) - 1\}^2}$$

The green channel of the updated channels image is used in the proposed method for the exudates segmentation.

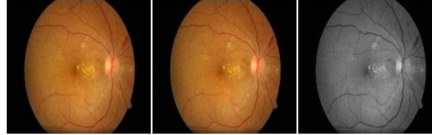

Fig. 2 Image Normalization (a) Original Input image (b) Normalized Input image (c) Green channel of the normalized image

### B. Adaptive Threshold Selection:

The histogram of the green channel image is analyzed and used to determine a suitable threshold for segmentation of exudates. However, to make this threshold adaptive and suitable for all images of a particular database, first order statistical parameters, such as mean and standard deviation, were used along with Otsu's threshold. The threshold used for segmenting the exudates is as follows:

$$Th = \{(0.8 * \text{mean}(I)) + \text{std}(I)\} / 255 + \text{graythresh}(I)$$

Where,  $Th$  is the adaptive threshold for exudates segmentation,

$I$  is the normalized green channel

$\text{Graythresh}(I)$  is the Otsu's threshold.




Fig. 3 Exudates candidates (a) Green channel (b) Histogram of green channel (c) Segmented bright pixels from the image

### C. Elimination of False Positives:

In case of exudates segmentation, the false detecting candidates were observed to be the optic disc pixels. So, some method is needed to segment the optic disc and remove the false positive pixels. To segment the optic disc, its center is found out and a circle is drawn using some predefined radius to eliminate the OD pixels from the thresholded image. For localization of the optic disc, an averaging filter is used to blur the grayscale image of the colored fundus image. A maximum point on the image is found and shifted by a few pixels to determine an approximate center of the optic disc. Using this center a circle is drawn to remove the OD pixels which were detected as false positives.

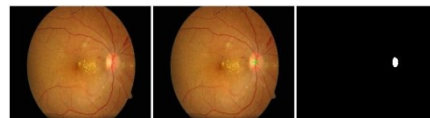

Fig. 4 Optic Disc Localization (a) Input Image (b) Input Image with marked OD center (c) OD pixels segmented using the threshold

### D. Final Segmentation of Exudates:

The final segmentation of the exudates is done by removing the optic disc pixels which were detected as false positives in the earlier segmented image. The binary image with optic disc detected is subtracted from the image that contains possible exudates candidate image. The resultant image contains the exudates which are present in the test image.

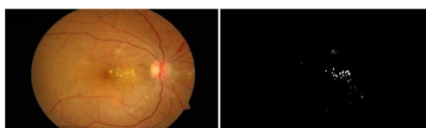

Fig. 5 Final Segmented Exudates (a) Input Image (b) Exudates

## Experimental Results

The proposed method has been tested on 70 images which were collected from a local hospital. These images consisted of both healthy and unhealthy images. Out of the 70 images, 35 images had bright lesions while the remaining 35 images did not have any lesions and were normal. Fig. 6 shows the segmentation results for some of the samples from the images used for experimentation.

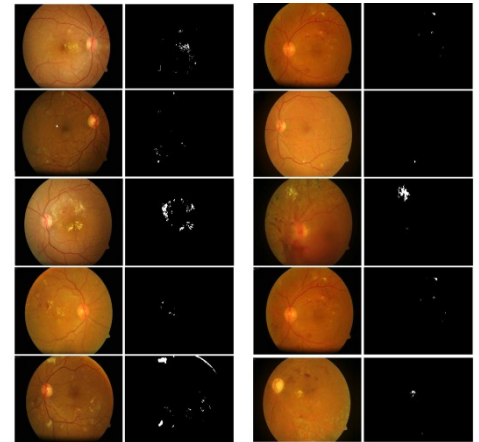


Figure 6. Experimental Results (a) Input Image (b) Segmented Exudates

Table 1 gives the time required by proposed method for exudates segmentation. It can be summarized from the table that the computation time needed for segmentation is very less and this can be considered as a significant development towards automated detection of exudates from fundus images.

TABLE I.COMPUTATION TIME

Samples	Computational Time (in secs)
Sample 1	8.4327
Sample 2	9.1755
Sample 3	13.2607
Sample 4	11.3398
Sample 5	6.3434
Sample 6	6.2732
Sample 7	9.4640
Sample 8	9.6177
Sample 9	13.2258
Sample 10	7.7808
Sample 11	8.4579
Sample 12	9.0204
Sample 13	8.9647
Sample 14	7.9987
Sample 15	9.6483

## Conclusions

The proposed method for automatic detection of exudates in the fundus images can be very helpful in the diagnosis of diabetic retinopathy (DR) at earlier stage. In this paper, a method to segment the exudates from fundus images using an automated thresholding is proposed. The adaptive thresholding is efficient and beneficial as it depends on features from the image itself and can be used independently for different fundus images. The method used for localization of the optic disc is also efficient. The proposed algorithm has been tested upon a database and proved out to be efficient. The encouraging results from the algorithm make it suitable for real time applications.

## Acknowledgement

This work was supported in part by the Grants from Department of Science and Technology, No. DST/TSG/ICT/2013/37. Also the authors express their thankfulness to Dr. S.C. Gupta, Medical Director of Venu Eye Research Centre for his kind support.

