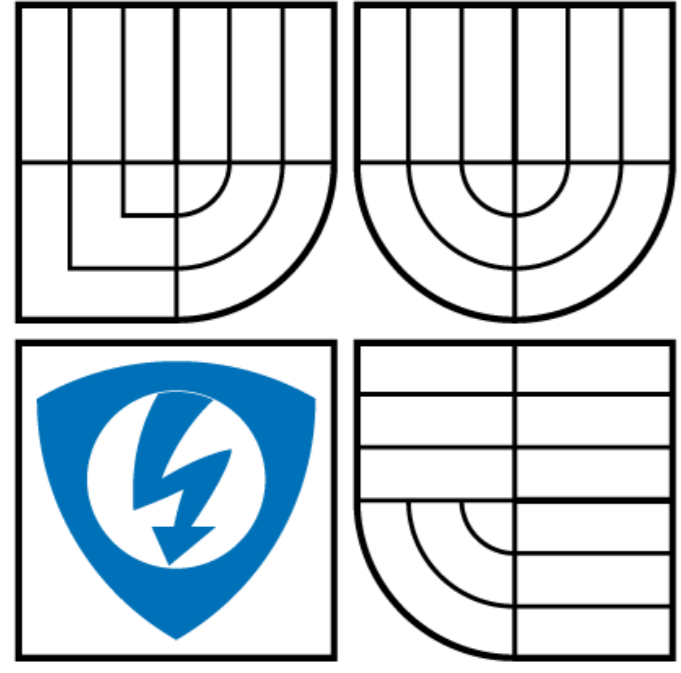


Exudates Detection in Digital Fundus Image Using Edge Based Method and Strategic Thresholding



Kshitij Srivastava¹, Shaunak Ganguly¹, Shaumik Ganguly¹, Malay Kishore Dutta¹, M Parthasarathi¹, Radim Burget² and Jiri Prinosil²

¹Amity School of Engineering & Technology, Amity University, Noida, India
²SPLab, Department of Telecommunications, FEEC, Brno University of Technology
 Technicka 12, 616 00 Brno, Czech Republic.

1. Introduction

The paper proposes an image processing algorithm to accurately detect the presence of exudates in Fundus images. For Diabetic Retinopathy, presence of exudates in the fundus image marks the beginning of vision loss and hence detecting the exudates accurately and efficiently is of prime concern. The proposed algorithm is a strategic method which removes false detection because of noise generated for different reasons. Using a strategic combination of two independent approaches based on threshold and edge detection helps in eliminating all possible types of noises leading to false exudates that may have crept in. Both these approaches have different sources of error. Hence, this method of detecting the exudates has an advantage of increased accuracy. Experimental results indicate that this method has a clear advantage of accuracy in terms of exudates detection in the digital Fundus image without compromising the computational time.

2. Proposed Algorithm

The proposed algorithm of detection is based on two independent approaches to detect exudates, as shown in Fig 1. The first method is based on intensity thresholding, which utilizes the higher intensity levels of exudates as compared to the background. The second method is gradient based detection technique which exploits the boundaries of exudates. A logical operation of the results of both the methods has been employed to remove the false positives which are created due to different conditions.

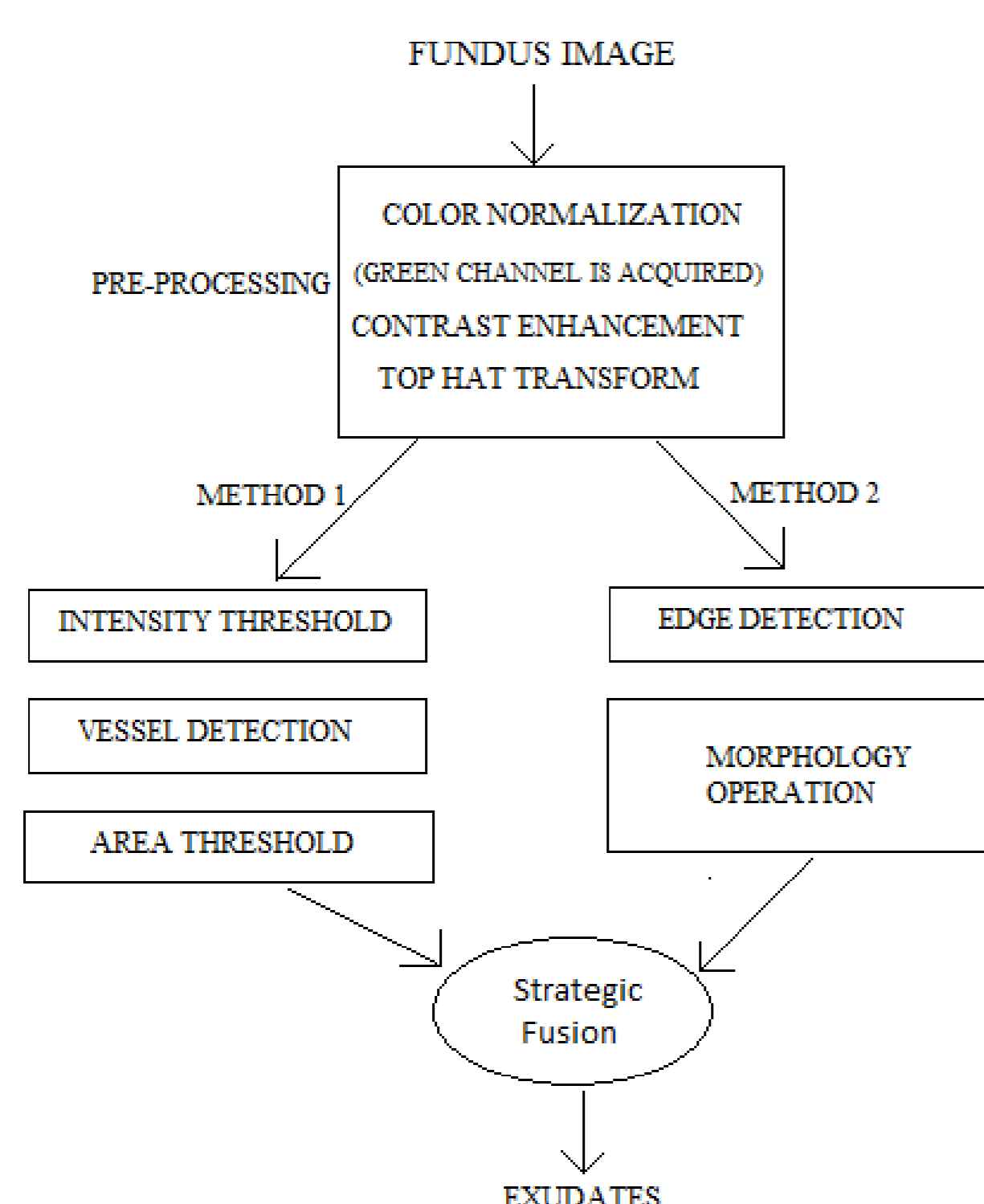


Figure 1: Block Diagram of the proposed method

Preprocessing of fundus images is required at the beginning. Color normalization is important in order to unify the color properties of all the images. Moreover, exudates are bright regions, hence contrast enhancement has a significant impact in differentiating the bright regions from the background. Adding to this, top-hat transform has been used as a measure of background shade correction. After preprocessing of the given fundus image, it is converted into binary format. Thus, every pixel with intensity higher than the applied threshold is represented as a white pixel and every other pixel is represented with a black pixel. After, the intensity thresholding, the image is also passed through a median filter in order to eliminate the granular noise present in the image. It can be seen in Fig. 2 that the grayscale fundus image is now converted into a binary image which has all the exudates. But, this step is not a noiseless step, so it includes noise mainly in the form of Optic Disk (OD) and also due to uneven brightness.




Figure 2: Fundus image after binary conversion

It can be observed that the OD is detected as broken sectors. This is due to the blood vessels, which are of dark intensity, going in the OD. Hence, the blood vessels have been detected using Matched Filter and Derivative of Gaussian. The image with detected vessels is then added on to the binary converted image in Fig. 2. Thus, the Optic Disk along with the surrounding noise particles form a single object of large area. Hence, the image is then thresholded based on area. Fig. 3 shows the result of area thresholding, where it is evident that the Optic disk has been removed efficiently.




Figure 3: Fundus after Area thresholding

The second method follows an altogether different approach to detect the exudates. The first step for this method is to detect pixels with high gradient, in other words detection of areas with high frequency or detection of the contours and edges present in the fundus image. Canny Edge detector with a threshold of 0.15 serves the purpose in detecting the contours of the exudates. This low threshold helps to preserve maximum information. Next, morphological operation of closing, with a disk shaped structuring element of 8 pixels, is performed. Fig. 4 shows the resultant of this operation, where all the exudates are detected along with the dilated blood vessels.

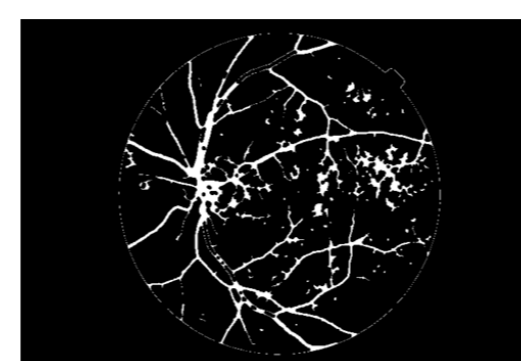


Figure 4: Edge Based detection of Exudates

A logical-AND operation is done to include only those exudates which are detected from both the methods and are common from the results of the two methods which were carried out. For the method using intensity thresholding, the major source of error is the Optic Disk. Optic Disk is a bright region of considerably large size, which has similar intensity levels to that of exudates. Another source of error in some images is the region around the Optic Disk consisting of small bright dots. On applying intensity thresholding, these similar intensity pixels are also detected. In the other method using edge detection, apart from the edges of the exudates, it also detects the edges of the blood vessels and micro-aneurysms.

3. Results and Discussion

The algorithm was successfully implemented and positive results were obtained which can be seen from the Table 1. On implementing only the intensity thresholding and area thresholding method, the proportion of false positives detected as exudates was quite high, whereas, the results after the strategic combination with the edge-based detection showed a stark improvement in results by reducing the proportion of false positives.

Table 1: Pixel Count of Detected False Positives

Stage	Method 1 (Intensity) (False Positives)	Method 2 (Contour) (False Positives)
Normal	5403	0
Moderate	3316	1149
Severe	13349	0
Proliferative	4119	2476

Table 2: Comparison of Computation Time

Sample	Stage	Computation Time for Method 1 (seconds)	Computation Time for Combined Method (seconds)
Sample 1	Normal	99.104453	104.566743
Sample 2	Moderate	95.563452	98.667324
Sample 3	Severe	101.459954	106.452264
Sample 4	Proliferative	97.554673	100.956783

For subjective perception and evaluation, results of some fundus images have been shown in Fig. 5 and Fig. 6. The figures include the given fundus image, along with the detected exudates after implementing the first method only and then the final result of detected exudates. The regions detected as exudates have been represented as * for a better understanding. It should be noted that without increasing much computational complexity as shown in Table 2, a major portion of noise or False positives can be eliminated.

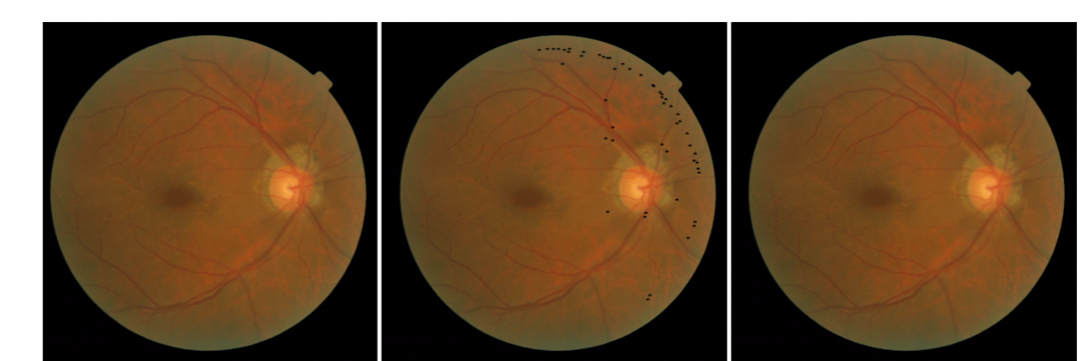


Figure 5: (Left) Input (Normal), (Centre) Result of method 1, (Right) Result of the proposed method.

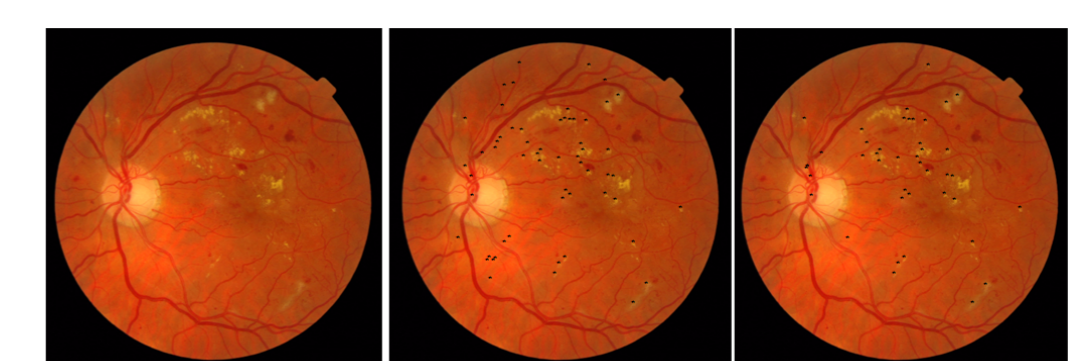


Figure 6: (Left) Input (Proliferative), (Centre) Result of method 1, (Right) Result of the proposed method

4. Conclusion

The proposed methodology of detecting the presence of exudates has been done by strategic combination of intensity thresholding and edge based detection. These two independent methods of detection which works on different principles have been fused to remove false positive detections. Edge detection method helps in determining the boundary of the exudates whereas intensity based thresholding method works on the principle of extracting the objects from the image having maximum intensity. There are some false detection in both the methods. Strategic combining these two methods helps us in removing two different types of noises and helps in more accurate detection of exudates. The experimental results indicate that the accuracy of the proposed method is superior to single intensity thresholding method.

5. Acknowledgement

This work was supported in part by the Grants from Department of Science and Technology, No. DST/TSG/ICT/2013/37, Government of India and by SIX CZ.1.05/2.1.00/03.0072, OPVK EE.2.3.20.0094, MPO FR-TI4/151, and VUT BD18116001, Czech Republic.

