

## Introduction

The proposed work presents an image processing technique for segmentation of optic disc and cup based on adaptive thresholding using features from the image. The proposed algorithm uses the features obtained from the image, such as mean and standard deviation, to remove information from the red and green channel of a fundus image and obtain an image which contains only the optic nerve head region in both the channels. The optic disc is segmented from the red channel and optic cup from the green channel respectively. The threshold is determined from the smoothed histogram of the preprocessed image. The results of the proposed algorithm are compared with the images that are marked by doctors. The accuracy of the algorithm is good and is computationally very fast. The proposed method can be used for screening purpose.

## Proposed Algorithm

The block diagram of the proposed algorithm is as shown in Fig 1. The optic disc is extracted from the red channel while the optic cup is extracted from the green channel of the fundus image. The red and green channels are preprocessed and the histograms of the preprocessed channel images are smoothed using a Gaussian filter to select an adaptive threshold which is solely based on the local statistical features of the fundus image.

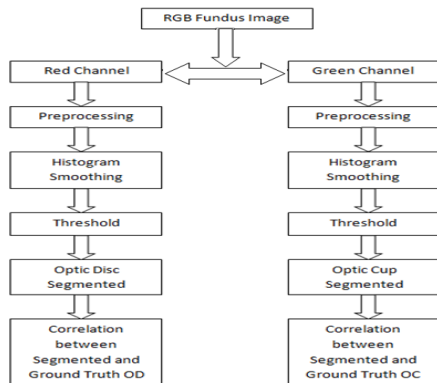


Figure 1. Block Diagram of Proposed Algorithm

Glaucoma is a disease related to the optic nerve head (ONH) region. So, in order to segment the ONH, preprocessing of fundus images is needed. In the preprocessing step, the local statistical features, such as mean and standard deviation, from the image are used and subtracted from the image iteratively. This preprocessing step highlights only the ONH region in the fundus image. The preprocessing is applied to red channel and green channel for optic disc and cup segmentation respectively. The preprocessed images are as shown in Fig 2.

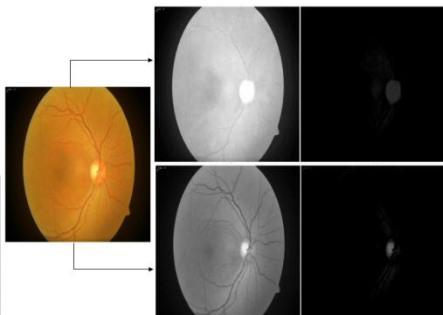


Figure 2. Preprocessing (a) Input Image (b) Red Channel (c) Preprocessed Red Channel (d) Green Channel (e) Preprocessed Green Channel

The histograms of the preprocessed are used to find the threshold for the optic disc and cup segmentation. The

intensity of the gray levels is shown on horizontal axis while the number of pixels having a gray level is shown on the vertical axis. The different peaks in a histogram show the different parts of the inner eye. The first peak is considered to be that of background pixels as they have low gray level intensities while the last peak is considered to be of the optic disc and cup as they have bright pixels with a high gray level intensity. The histograms of the preprocessed images are convolved with a Gaussian filter for smoothing as shown in Fig 3.

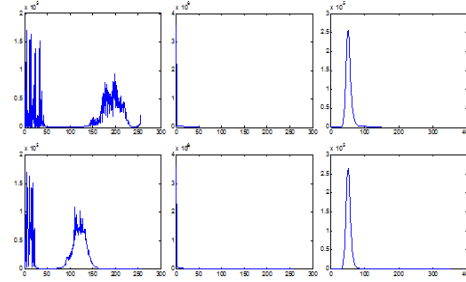


Figure 3. Histogram (a) Original red channel (b) Preprocessed red channel (c) Smoothed red channel (d) Original green channel (e) Preprocessed green channel (f) Smoothed green channel

The thresholds, T1 & T2, for segmentation of optic disc and cup are selected from the smoothed histograms. These are shown in Fig 4. and are given as follows:

$$T1 = (0.5 * m) - (2 * \sigma R) - (\sigma RI) \quad (1)$$

$$T2 = (0.5 * m) + (2 * \sigma G) + (2 * \sigma GI) + (\mu GI) \quad (2)$$

where, T1 = threshold for segmentation of optic disc  
T2 = threshold for segmentation of optic cup  
m = size of Gaussian window  
 $\sigma G$  = standard deviation of Gaussian window  
 $\sigma RI$  = std dev of the preprocessed red channel  
 $\sigma GI$  = std dev of the preprocessed green channel  
 $\mu GI$  = mean of the preprocessed green channel

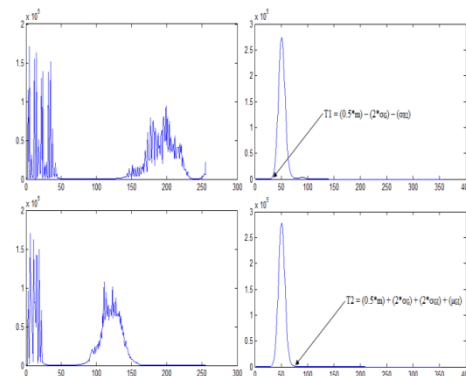


Figure 4. Histogram (a) Original Red channel (b) Smoothed preprocessed red channel with threshold (c) Original green channel (d) Smoothed preprocessed green channel with threshold

The selection of fixed value of threshold may not work on all sample images and might result in improper segmentation of optic disc and optic cup. This is because every image is independent having different levels of image properties and noise contents. If the threshold is determined from the local features of the image then the accuracy of segmentation may improve. This concept is used in this proposed approach and an adaptive threshold is selected which is based on the statistical features of the preprocessed image samples. The threshold is not selected from the histogram of the raw image. Instead, every image is standardized based on its inherent statistical features and the resultant image is suitable for threshold selection making the algorithm adaptive. The process of histogram smoothing is used to decide the threshold so that the chosen threshold in

the original histograms of the preprocessed channels corresponds to the points as shown in the smoothed histograms. These points correspond to the starting point of the primary peak in the smoothed histogram of red channel for optic disc segmentation. The same process is used for green channel to determine threshold for optic cup segmentation in which the selected threshold in the original image corresponds to the termination point of the primary peak in the smoothed histogram.

## Results

The proposed algorithm was successfully implemented on 63 fundus images and the results can be seen from Table 1. Table 1 shows the comparison between the segmented results and the ground truth images marked by the doctor. The comparison is done by finding the correlation coefficients between the segmented images marked with ground truth and the segmented images obtained from the algorithm. The morphological operations such as closing and opening are performed on the segmented optic disc and cup. From the correlation coefficients obtained from both the cases, it can be concluded that the results were better when morphological operation is performed on the segmented disc and cup. The structuring element used to perform the morphological closing and opening is disk shaped. For better results, the size of the structuring element used should be more than the thickness of the primary blood vessel.

Table 1: Correlation Coefficients Between Segmented And Ground Truth Optic Disc And Optic Cup

Sample	Correlation Between Morphology)	Coefficient (Without Morphology)	Correlation Between Morphology)	Coefficient (With Morphology)
	Segmented OD & Ground Truth OD	Segmented OC & Ground Truth OC	Segmented OD & Ground Truth OD	Segmented OC & Ground Truth OC
Sample 1	0.9727	0.7462	0.9628	0.73
Sample 2	0.9384	0.8663	0.9426	0.8927
Sample 3	0.8262	0.8525	0.777	0.8754
Sample 4	0.9042	0.8701	0.9486	0.874
Sample 5	0.8329	0.8719	0.8715	0.8651
Sample 6	0.957	0.7802	0.9606	0.8439
Sample 7	0.776	0.7514	0.8221	0.7936
Sample 8	0.8827	0.805	0.9431	0.8715
Sample 9	0.9633	0.8467	0.9414	0.8928
Sample 10	0.8863	0.8929	0.9156	0.8829

## Conclusions

The proposed methodology to segment the optic disc and cup from a fundus image is accurate and efficient. The common challenge in glaucoma detection is the accurate segmentation of optic disc which can be affected due to presence of peri-papillary atrophy (PPA). However, in the proposed work, this shortcoming is overcome as only the brighter pixels will be threshold. The proposed algorithm worked on the images of MESSIDOR database also. The algorithm failed on 5 images out of 63 images from the local hospital. The proposed algorithm segmented the optic disc and cup to an accuracy of 92.06%. The algorithm is computationally fast and produces the segmentation of both disc and cup in 3.313 seconds.

The proposed algorithm is an efficient framework and it can be used for automatic diagnosis of glaucoma in screening programs.

## Acknowledgement

This work was supported in part by the Grants from Department of Science and Technology, No. DST/TSG/ICT/2013/37. Also the authors express their thankfulness to Dr. S.C. Gupta, Medical Director of Venu Eye Research Centre for his kind support.

